

PET-CT CASE OF THE MONTH

David W. Seldin, M.D. Franklin Square Hospital Center August 2006

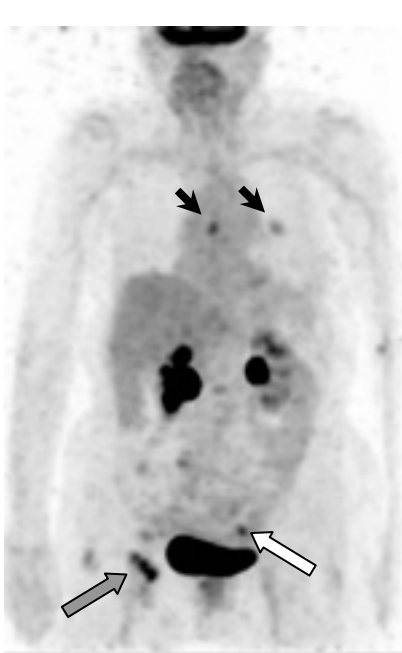


Fig. 1

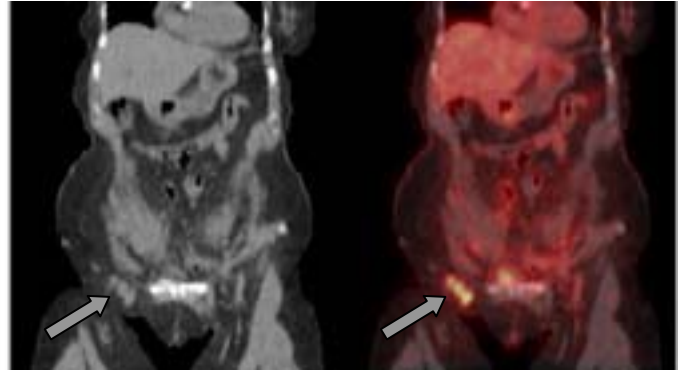
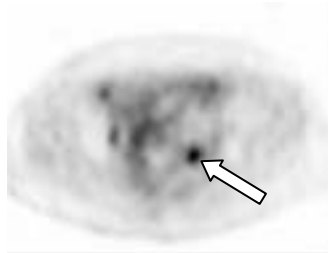
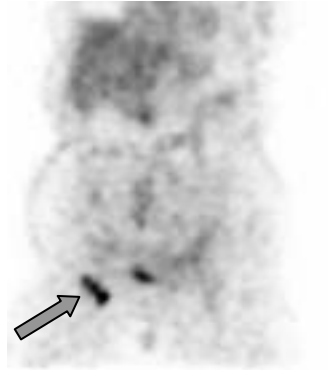


Fig. 2

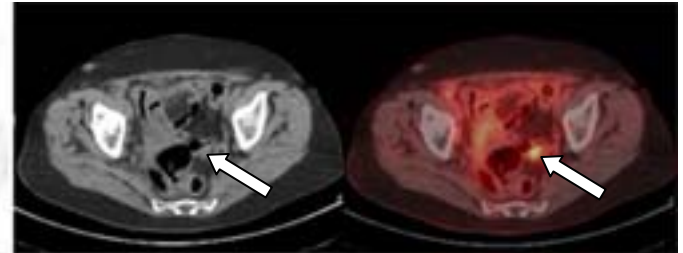


Fig. 3

This 77 year old woman had a history of right radical mastectomy for ductal carcinoma 16 years earlier. Four years ago she presented with metastatic breast carcinoma in a right neck lymph node, for which she received hormonal therapy. An adenocarcinoma in the bladder was recently discovered and a cystectomy was suggested. A PET-CT was ordered for additional staging information and restaging of the breast cancer.

The PET-CT showed uptake in a subcarinal lymph node and a left lung nodule (Fig. 1, arrowheads). Tracer uptake was also present in three right inguinal lymph nodes (Figs. 1 and 2, gray arrows) and a left iliac lymph node (Figs. 1 and 3, white arrows). The right inguinal adenopathy had not been detected clinically. An ultrasound guided right inguinal lymph node biopsy showed a poorly differentiated adenocarcinoma which immunostains indicated was of breast origin. The histology was identical to the prior bladder lesion, and immunostains were obtained from the bladder specimen showing it represented a breast metastasis.

How did the PET-CT help? :

PET-CT demonstrated abnormal right inguinal nodes, which when biopsied lead to the diagnosis of only metastatic breast cancer, rather than an additional primary cancer in the bladder. Inappropriate treatment was therefore avoided.

Recent studies have shown the utility of PET for staging and restaging women with breast carcinoma^{1,2}.

(1) Br J Surg. 2005 Nov;92:1363-7

(2) J Clin Oncol. 2004 Apr 1;22:1253-9