

PET CASE OF THE MONTH

Gabriel Soudry, M.D. September 2002

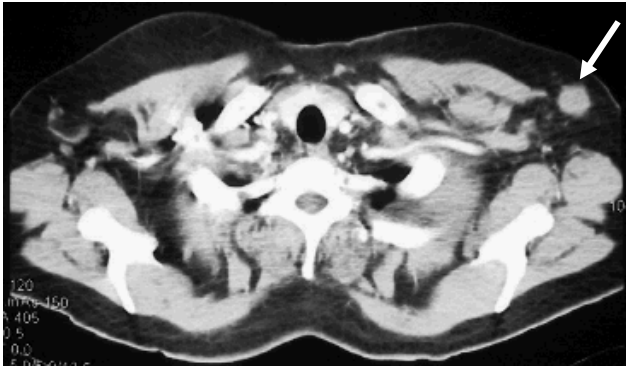

Fig.1

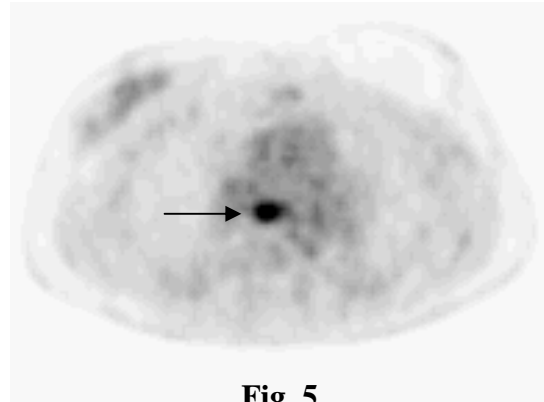


Fig. 5

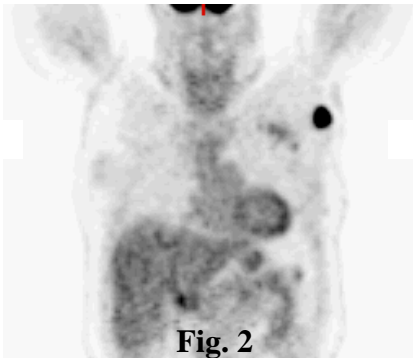


Fig. 2

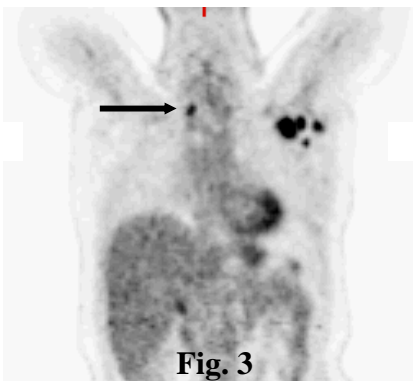


Fig. 3

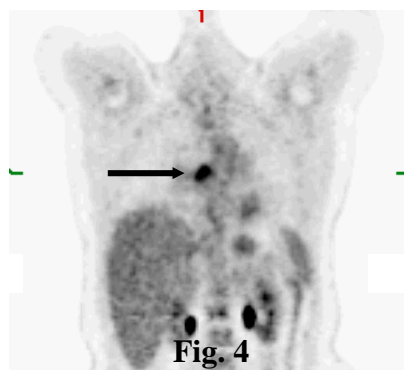


Fig. 4

This 49 year old lady underwent a left mastectomy two years prior. Pathology showed infiltrating moderately differentiated adenocarcinoma. No nodes were found in the axillary contents. The patient refused adjuvant chemotherapy or radiation therapy. During a recent follow-up, she was found to have a palpable left axillary node. Ultrasound guided core biopsy of that node revealed metastatic adenocarcinoma consistent with breast origin. A subsequent chest CT (Fig. 1) reported a 1.5 cm round mass in the left axilla and no additional abnormalities.

A PET scan was ordered to restage the patient, which showed:

- A metastatic left axillary node (Fig. 2) corresponding to the CT finding
- Multiple additional left axillary nodes (Fig. 3) as well as a right paratracheal node (arrow)
- A subcarinal mediastinal node (Fig. 4) also seen on the transverse image (Fig. 5)

Why did the PET help: PET allowed a more complete evaluation of the extent of disease. Based on the PET result, the patient may benefit from systemic therapy before considering additional surgery.

In a recent study involving 73 patients, PET was compared to CT in the detection of mediastinal or internal mammary metastases in **breast cancer**. PET accuracy was found to be 88% as compared to 73% for CT (1). In another study, PET had a major impact on the management of breast cancer patients, influencing both the clinical stage and management in more than 30% of patients (2).

(1) J Clin Oncol 2001;19:3516-3523

(2) J Nucl Med 2001;42:1334-1337